

# Extensor Tendon Injuries

Jonas L. Matzon, MD, David J. Bozentka, MD

The extensor mechanism of the fingers, hand, wrist, and forearm is extremely intricate. Disruptions to the extensor system are common and can be associated with poor patient outcomes when not treated appropriately. Although extensor tendon injuries receive much less attention in the literature than flexor tendon injuries do, several recent studies have examined this topic. This article presents an overview of the treatment of extensor tendon injuries, with a focus on recent developments. (*J Hand Surg* 2010;35A:854–861. © 2010 Published by Elsevier Inc. on behalf of the American Society for Surgery of the Hand.)

**Key words** Extensor tendon injury, extensor tendon mechanism, extensor tendon reconstruction.

## ANATOMY

In the forearm, the extrinsic extensor tendons can be divided into superficial and deep muscular components. The superficial group includes the extensor carpi radialis longus, the extensor carpi radialis brevis, the extensor digitorum communis (EDC), the extensor digiti minimi (EDM), and the extensor carpi ulnaris. The deep group is composed of the abductor pollicis longus, the extensor pollicis brevis, the extensor pollicis longus, and the extensor indicis proprius (EIP). The brachioradialis and extensor carpi radialis longus are innervated by the radial nerve. The extensor carpi radialis brevis is supplied by branches from the posterior interosseous or superficial radial sensory nerve.<sup>6,14</sup> All the other extrinsic extensor muscles are innervated by the posterior interosseous nerve.

At the level of the wrist, the extensor tendons travel through 6 dorsal compartments to gain access to the hand. The first dorsal compartment contains the abductor pollicis longus and extensor pollicis brevis tendons. Septation of the first compartment occurs in 20% to 60% of patients, and multiple slips of abductor pollicis

longus tendon are commonplace.<sup>16</sup> The second fibro-osseous tunnel includes the extensor carpi radialis longus and extensor carpi radialis brevis tendons, with the brevis tendon located ulnarly. The third compartment contains the extensor pollicis longus tendon, as it lies ulnar to Lister's tubercle. The fourth contains the EDC and EIP tendons. The terminal branch of the posterior interosseous nerve is found within the base of this compartment. The EDM tendon is located in the fifth compartment, which lies over the distal radial ulnar joint. The sixth compartment contains the extensor carpi ulnaris tendon.

After coursing through these fibro-osseous tunnels, the extrinsic tendons become more superficial and flat. In the hand, the extensor tendons can have considerable variation. The most common pattern includes a single EIP, which inserts deep and ulnar to a single EDC tendon to the index finger. The EDC tendon to the small finger is often absent, and a double EDM tendon occurs in 89% of cases.<sup>10</sup>

As the finger extensors travel distally, the complexity of the system increases (Fig. 1). Proximal to the metacarpophalangeal (MCP) joint, juncturae tendinum provide interconnections between the EDC tendons. At the MCP joint, the sagittal bands form a sling around the extensor tendon radially and ulnarly attaching to the volar plate. The sagittal bands centralize the EDC tendon and aid in MCP extension. Distal to the MCP joint, the intrinsics (lumbricals and interosseous muscles) join the extensor mechanism. The interossei split into medial and lateral slips. The medial slips insert on the base of the proximal phalanx and flex the MCP

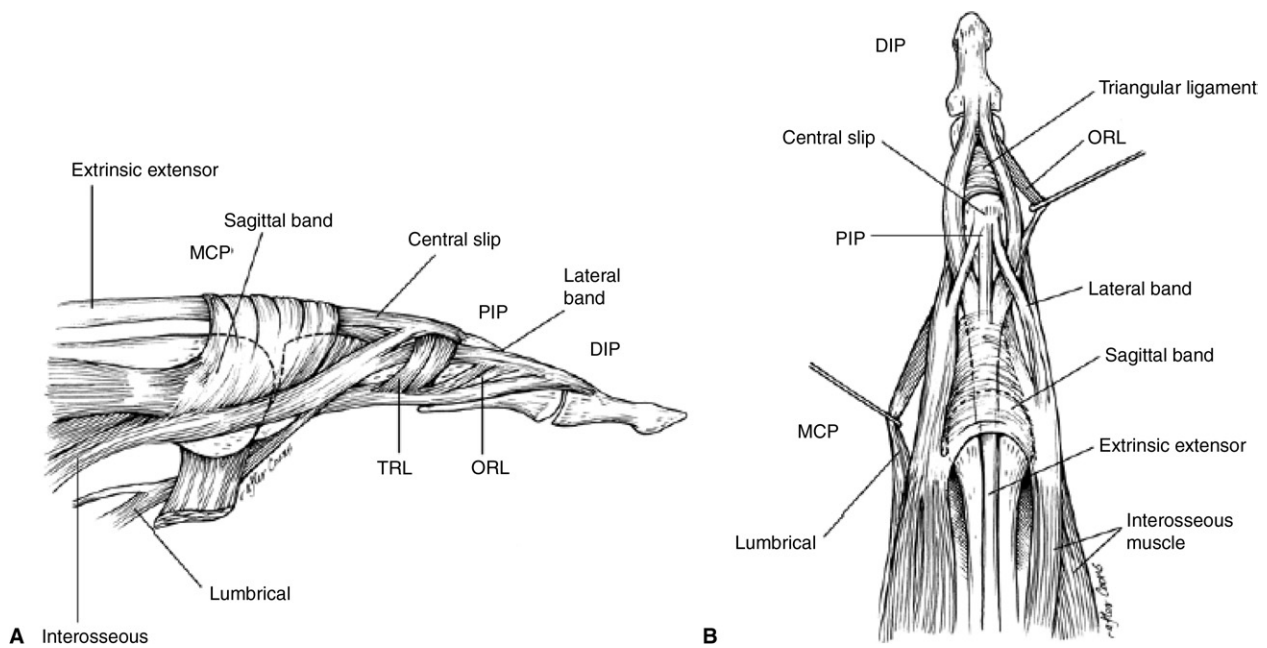
From the Department of Orthopedic Surgery, Penn Presbyterian Medical Center, Philadelphia, PA; and the Curtis National Hand Center, Union Memorial Hospital, Baltimore, MD.

Received for publication February 14, 2010; accepted March 1, 2010.

No benefits in any form have been received or will be received related directly or indirectly to the subject of this article.

**Corresponding author:** David J. Bozentka, MD, Department of Orthopedic Surgery, Penn Presbyterian Medical Center, 1 Cupp Pavilion, 51 N. 39th Street, Philadelphia, PA 19104; e-mail: David.Bozentka@uphs.upenn.edu.

0363-5023/10/35A05-0032\$36.00/0  
doi:10.1016/j.jhssa.2010.03.002



**FIGURE 1:** **A** lateral view, **B** dorsal view. Finger extensor mechanism anatomy. Reprinted with permission from Coon MS, Green SM. Boutonniere deformity. *Hand Clinics* 1995;11:387–402. Copyright 1995, with permission from Elsevier.

joint. The lateral slips, joined by the lumbrical on the radial side, contribute to the extensor mechanism. Transverse fibers of the interossei (transverse retinacular ligament) form a sling over the proximal phalanx that aids in MCP flexion. At the proximal interphalangeal (PIP) joint, the common extensor tendon trifurcates into 2 lateral bands and a central slip. The central slip inserts at the base of the middle phalanx to extend the PIP joint. The lateral bands coalesce with the lateral slips from the intrinsics (interossei and lumbricals) to form the conjoined lateral bands. The 2 conjoined lateral bands coalesce into the terminal tendon, which inserts at the base of the distal phalanx to extend the distal interphalangeal (DIP) joint. The triangular ligament prevents the conjoined lateral bands from volar subluxation, and the transverse retinacular ligament prevents dorsal subluxation.

### EVALUATION, DIAGNOSIS, AND CLASSIFICATION

Detailed knowledge of extensor mechanism anatomy is necessary to properly diagnose injuries to the extensor tendon. Initial evaluation should include a thorough physical examination. Wounds should be closely inspected for size, location, and underlying injury. The extensor mechanism can be divided into 9 zones to aid in classification of these injuries (Fig. 2). Odd-numbered zones are located over joints, and even-numbered zones are located over bones. Zone I includes

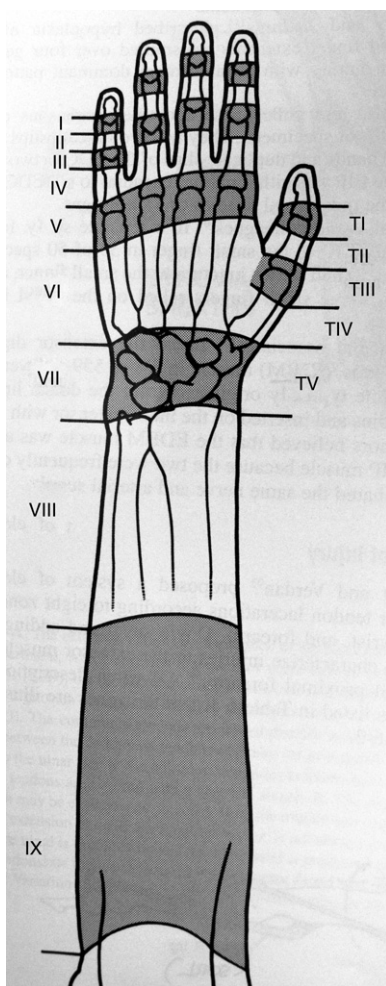
any injury to the terminal tendon over the DIP. Zone II injuries occur over the middle phalanx. An injury in zone III contains the PIP joint. Zone IV involves the proximal phalanx. Zone V contains the MCP joint. Zone VI involves the metacarpals. Zone VII includes the carpus and extensor retinaculum. Zone VIII involves the distal third of the forearm, up to the musculotendinous junctions of the extensors. Zone IX involves the remaining part of the forearm. The thumb has a unique classification system, given that it has one fewer phalanx. TI contains the interphalangeal joint, and TII involves the proximal phalanx. TIII contains the MCP joint, and TIV contains the metacarpal. Finally, TV encompasses the carpus.

Loss of the normal resting cascade of the hand often indicates a tendon injury. After inspection, the function of each extensor tendon should be tested with and without resistance. Each finger should be tested individually so that the juncturae tendinum do not mask an injury. To eliminate pain as a confounding variable, local anesthesia might be necessary. Given that extensor tendon injuries often do not occur in isolation, complete neurovascular examinations should be performed. Radiographs should be taken to evaluate for bone or joint injury.

### TREATMENT

#### Zone I

Injury to the terminal tendon at the DIP joint is considered a mallet finger. Typically, this injury pattern occurs



**FIGURE 2:** Extensor tendon zones of injury. Reprinted with permission from Baratz M, Schmidt C, Hughes T. Extensor tendon injuries. In: Green DP, Hotchkiss RN, Pederson WC, eds. Green's operative hand surgery. 5th ed. New York: Churchill Livingstone, 2005:187–217. Copyright 2005, with permission from Elsevier.

with forced flexion during active extension. Doyle classified this injury into 4 types.<sup>5</sup> Type I injuries are closed, whereas type II are open. Type III injuries are open, with loss of skin and tendon substance. Type IV injuries involve large mallet fractures. In general, closed injuries are treated closed with splints, and open injuries are treated open with surgical repair. However, injury chronicity, associated fracture, joint stability, injury mechanism, and underlying arthritis complicate this simple algorithm.

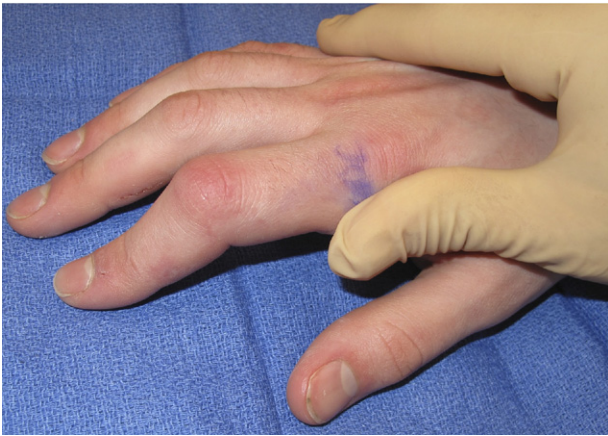Classically, type I mallet fingers are treated with DIP extension splinting for 6 weeks. If active DIP extension is still limited, full-time immobilization might need to be continued for up to a total of 3 months. When active DIP extension is maintained following immobilization, a nighttime extension splint is continued for an additional 4 to 6 weeks. Many splint options exist, and

splints should be chosen based on fit, comfort, availability, and cost. In 2009, Handoll and Vaghela updated their 2004 meta-analysis examining the relative effectiveness of different treatment methods for mallet finger injuries.<sup>17</sup> They identified only 4 studies that met inclusion criteria, and no new studies were found from 2005 to 2008.<sup>3,22,24,37</sup> They concluded that insufficient data exist to establish the relative effectiveness of different finger splints.<sup>17</sup> Whether a stack splint or a custom-made splint is used, the most important factor in achieving good outcomes is patient compliance with the splint.

Also, a search of the Cochrane Database failed to determine specific surgical indications for mallet finger injuries.<sup>17</sup> Historically, the surgical indications have been controversial but have included open injuries, instability of the DIP joint, or a fracture fragment greater than 30% to 50%. However, the literature does not define a critical fracture percentage that will cause instability. In a cadaveric model, Husain et al. demonstrated joint stability when the fracture fragment measured less than 43% of the articular surface and joint subluxation when the defect measured greater than 52% of the articular surface.<sup>18</sup> In a retrospective study, Kalainov et al. treated 21 patients with mallet fractures greater than one third of the articular surface nonsurgically and reported satisfactory outcomes in terms of pain and function.<sup>19</sup> However, their results were reported at only 2 years follow-up and would be expected to worsen with time, given early evidence of residual subluxation, dorsal prominences, swan-neck deformities, and degenerative arthritis.<sup>19</sup>

When surgery is indicated, many techniques are available and have been recommended. Primary repair can be performed using a variety of suture techniques and is typically supplemented with K-wire fixation of the DIP joint to protect the repair. The terminal tendon can also be successfully repaired with a pullout suture/button or a suture anchor. For mallet fractures, good results have been achieved using extension block pinning and, more recently, a hook plate.<sup>35,36</sup>

Overall, mallet fingers are extremely common. Although the literature supports nonsurgical treatment of the majority of these injuries with a splint, surgical indications remain unclear. In general, injuries with an associated fracture dislocation of the DIP joint are considered for surgical treatment. Given the paucity of available data, a prospective, randomized trial comparing surgical to nonsurgical treatment of large mallet fractures would be beneficial.



**FIGURE 3:** Zone III extensor tendon injury with boutonniere deformity.

### Zone II

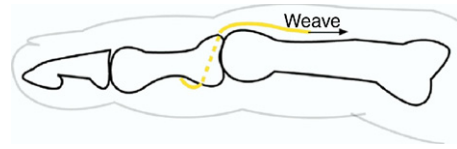
Zone II injuries occur over the middle phalanx and usually arise secondary to a laceration. Incomplete tendon injuries can be treated nonsurgically with a short, 1- to 2-week course of splinting, if greater than 50% of the tendon is intact, if no extensor lag exists, and if active extension occurs without weakness. Complete tendon injuries should be treated with primary repair. No studies have examined a specific suture technique in this zone. Options include a running stitch over-sewn with a Silfverskiöld cross stitch, a figure-of-eight stitch, or tenodesis.<sup>26</sup> All techniques can be supplemented with a longitudinal K-wire through the DIP joint in extension.

Rehabilitation after surgical management of zone II injuries is similar to that for zone I injuries. Strict immobilization with the DIP in extension is maintained for 6 weeks. Active and passive range of motion of the PIP and MCP joints are encouraged during this time to prevent stiffness. After 6 weeks, daytime active motion is permitted, as long as active DIP joint extension is maintained. While progressing with mobilization, nighttime extension splinting is continued for an additional 6 weeks.

### Zone III

Zone III injuries involve disruption of the central slip. Often, these injuries can be subtle, and vigilance is necessary for diagnosis. Patients usually present with PIP joint swelling, mild PIP joint extension lag, and weak PIP joint extension against resistance. The Elson test, which demonstrates rigidity of the DIP joint during attempted PIP extension from a flexed position, has been shown to reliably diagnose an early central slip injury.<sup>31</sup>

However, attenuation of the central slip can occur several weeks after an injury, so a high index of suspi-



**FIGURE 4:** Central slip reconstruction using a slip of flexor digitorum superficialis. Reprinted with permission from Ahmad F, Pickford M. Reconstruction of the extensor central slip using a distally based flexor digitorum superficialis slip. *J Hand Surg* 2009;34A:930–932. Copyright 2009, with permission from Elsevier.

cion should be maintained. In order to prevent progression, protective splinting of the PIP joint is considered after trauma to the central slip with associated swelling and tenderness. The goal is to prevent an untreated central slip injury from resulting in a boutonniere deformity with a flexed position of the PIP and hyperextension of the DIP (Fig. 3). The deformity develops secondary to loss of the extension force on the PIP, with volar subluxation of the lateral bands and subsequent DIP joint hyperextension.

Treatment of zone III injuries is similar to that of zone I injuries. Closed injuries can be managed by extension splinting of the PIP joint, assuming that full passive PIP joint extension and full passive DIP joint flexion can be achieved. As with mallet fingers, many splint options exist, but no one type has been shown to be superior. Full-time extension PIP joint immobilization must occur for 6 weeks, followed by 6 weeks of night-time splinting. Flexion stretching exercises of the DIP joint while holding the PIP joint in extension is performed throughout the treatment course. This exercise program promotes a pull of the lateral bands dorsally from the volar subluxated position.

Surgical treatment of central slip injuries is reserved for open injuries, displaced avulsion fractures of the middle phalanx, PIP instability, and failed nonsurgical treatment. Surgical options include primary repair for open lacerations and suture anchor repair for avulsions and distal central slip injuries. In a biomechanical cadaver study, Cluett demonstrated similar failure loads and failure mechanisms of primary repair and suture anchor repair.<sup>13</sup> Mini-fragment screws are considered for fixation of larger middle phalangeal base fractures. Central slip reconstruction is reserved for cases involving extensor tendon deficiency. Two popular techniques are Snow's central slip turndown and Aiache's central lateral band mobilization.<sup>2,33</sup> More recently, Ahmad and Pickford have described using a slip of flexor digitorum superficialis for central slip reconstruction<sup>1</sup> (Fig. 4). After central slip repair or reconstruction, no

consensus exists regarding transarticular pin fixation of the PIP joint to secure full extension.

After surgery, the traditional rehabilitation protocol is similar to that of nonsurgical management, with static extension splinting for 4 to 6 weeks. However, concerns have been raised regarding stiffness and limited tendon excursion. Evans has reported better results with an early active short arc motion protocol compared to static splinting.<sup>15</sup> Pratt retrospectively reviewed his more aggressive post-operative protocol that consisted of static extension immobilization for 3 weeks, followed by controlled mobilization in a Capener coil splint for an additional 3 weeks. His 27 patients (31 fingers) demonstrated good to excellent results, but 5 fingers had extension deficits.<sup>29</sup>

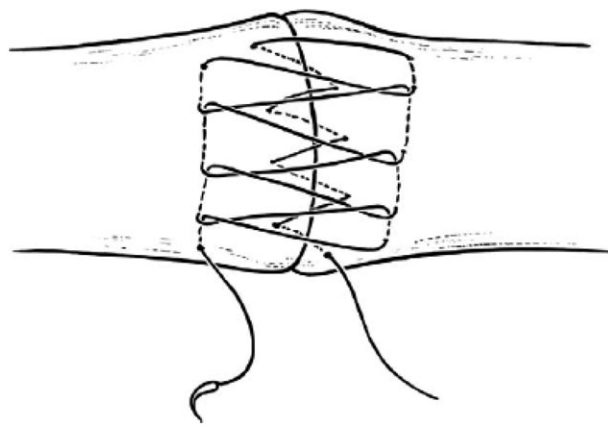
#### Zone IV

Similar to zone II injuries, zone IV injuries are most often secondary to lacerations. Because the tendon is flat and wraps around the proximal phalanx at this level, injuries are frequently partial. Therefore, a thorough physical examination that focuses on weakness to PIP joint extension is necessary to determine treatment. If there is no loss of extension, nonsurgical treatment with splinting and early motion is recommended.

However, if there is a loss of active extension, surgical exploration and tendon repair should be performed. In a biomechanical study, Newport found the Kleinert modification of the Bunnell technique and the modified Kessler technique to be the 2 strongest suture techniques.<sup>28</sup> Woo showed that the modified Becker suture technique has even higher ultimate strength.<sup>38</sup> More recently, in a cadaveric study, Lee et al. reported greater stiffness, less tendon shortening, and less time to perform the running, interlocking, horizontal mattress stitch than the Becker or Bunnell techniques (Fig. 5).<sup>23</sup> The implications of these biomechanical studies are that stronger suture techniques will allow early mobilization. Zubovic reported excellent clinical results in 18 patients using the augmented Becker technique.<sup>39</sup> Due to the strength of this repair, motion was started at 3 weeks. At final follow-up, no ruptures and a range of motion similar to that of the uninjured hand were noted.<sup>39</sup> Obviously, to be able to start early active motion, associated proximal phalangeal fractures, which are common, must also be repaired rigidly.

#### Zone V

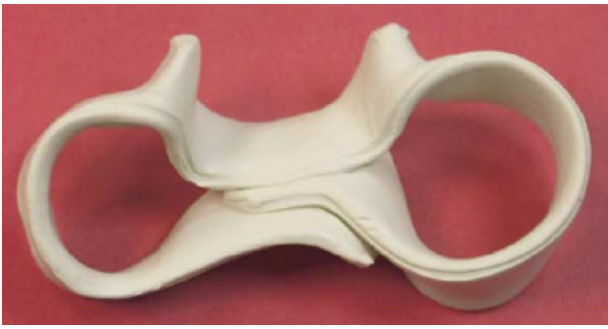Zone V injuries occur over the MCP joint, which is the most common location for extensor mechanism disruption. Frequently, these injuries happen during an altercation by a punch to another's mouth (called *fight bite*).



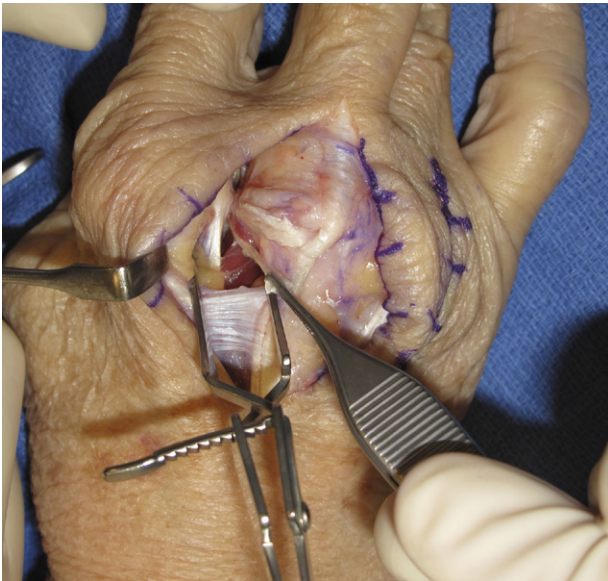
**FIGURE 5:** Running interlocking horizontal mattress stitch. Reprinted with permission from Lee SK, Dubey A, Kim BH, Zingman A, Landa J, Paksima N. A biomechanical study of extensor tendon repair methods: introduction to the running-interlocking horizontal mattress extensor tendon repair technique. *J Hand Surg* 2010;35A:19–23. Copyright 2010, with permission from Elsevier.

In these instances, the tendon injury is often of secondary importance compared to the risk of infection. Although the tendon is often only partially lacerated, the MCP joint is usually inoculated with mouth bacterial flora and eventually becomes septic. This requires surgical debridement, broad-spectrum intravenous antibiotics, and splinting.

Non-fight bite injuries also occur at this level (Fig. 2). Blunt trauma to the MCP joint can cause rupture of the sagittal bands, with subsequent extensor tendon subluxation. Diagnosis is made by observation, because patients have difficulty achieving full extension, and the extensor tendon can be seen on the ulnar aspect of the joint. Rayan and Murray have classified these injuries into 3 types.<sup>30</sup> Type I injuries involve a contusion without a tear. Type II is associated with subluxation of the extensor, with its border extending past the midline but maintaining contact with the metacarpal head condyle. Type III involves a dislocation of the tendon between the metacarpal heads. Patients with type II and III injuries experience snapping of the tendon with flexion and extension, and patients with type III injuries might have difficulty in actively extending the digit from full flexion.<sup>30</sup> Treatment depends on the chronicity of the injury. Acute injuries can be treated with extension splinting of the MCP joint for 6 weeks. Catalano et al. have reported good results treating long and ring finger, nonrheumatoid, acute, traumatic extensor tendon dislocations with a customized splint called the *sagittal band bridge*<sup>9</sup> (Fig. 6). The splint is fabricated with the injured MCP joint immobilized for 8 weeks in 25° to 35° of hyperextension relative to the adjacent



**FIGURE 6:** The sagittal band bridge splint. Reprinted with permission from Catalano LW III, Gupta S, Ragland R III, Glickel SZ, Johnson C, Barron OA. Closed treatment of nonrheumatoid extensor tendon dislocations at the metacarpophalangeal joint. *J Hand Surg* 2006;31A:242–245. Copyright 2006, with permission from Elsevier.



**FIGURE 7:** Sagittal band reconstruction.

MCP joints. Chronic injuries or those that fail immobilization are treated with primary repair rather than sagittal band reconstruction. When direct repair is impossible because of poor tissue quality, various surgical techniques that reconstruct the radial sagittal band using a distally based slip of the extensor tendon or juncturae are considered (Fig. 7). Recently, Segalman described a new technique using a dynamic lumbrical muscle transfer that has the benefit of being extra-articular and, therefore, minimizing stiffness.<sup>32</sup> In this technique, the lumbrical is harvested just proximal to its insertion and then passed through a small longitudinal splint in the extensor tendon at its isometric point. Correct tensioning of the transfer is vital to avoid radial subluxation with over-tensioning and ulnar subluxation with under-tensioning.

### Zone VI

Zone VI injuries occur over the metacarpals and are usually associated with better outcomes than more distal injuries are. The better prognosis is related to fewer associated joint injuries, decreased adhesion formation, and less chance of tendon imbalances.<sup>4</sup> Diagnosis of extensor tendon injury at this level can be challenging because the patient might still be able to extend the MCP joint via the EIP, EDM, and/or junctura tendinum. Therefore, it is critical to have a high index of suspicion and to thoroughly evaluate for extension weakness.

Because of the increased tendon diameter, surgical treatment should consist of a core suture. As stated in the discussion of zone IV injuries, the modified Becker and running, interlocking, horizontal mattress suture techniques are considered to allow earlier mobilization.

### Zone VII

Zone VII injuries involve damage to the extensor retinaculum. Although the extensor retinaculum is necessary to prevent bowstringing, it usually needs to be at least partially released for visualization. Often, release can be performed by a step-cut or z-cut so that it can be successfully closed after the tendon repair. When exposure is sufficient, dissection should proceed into normal anatomy to correctly identify cut tendon ends and other potentially injured structures such as sensory nerves. After all tendon ends are matched, repair should proceed with a core suture.

Chronic tears or ruptures in zone VII are difficult to manage. A common scenario is an extensor pollicis longus rupture after nonsurgical treatment of a minimally displaced distal radius fracture. Another example is extensor tendon rupture secondary to prominent hardware from volar or dorsal fixation of distal radius fractures. These injuries are not amenable to primary repair, and therefore, tendon transfer or grafting is the treatment of choice.

### Zones VIII and IX

Extensor tendon injuries at the forearm level usually involve the musculotendinous junction or the muscle belly. The biggest problem encountered at this level is the quality of tissue available for repair. Often one must search within the central aspect of the muscle belly for tendon tissue to repair. The most proximal injuries might have only a thin piece of fascia that overlies the muscle to provide tissue to suture. Surgical repair of these injuries is usually performed using multiple figure-of-eight stitches with slowly absorbing suture. Besides injury to the tendon itself, lacerations in this

region can be accompanied by nerve injuries, so a careful examination must be performed.

## REHABILITATION

Most of the recent research on extensor tendon injuries has focused on postoperative rehabilitation. Traditionally, extensor tendon repairs were immobilized to protect the surgical repair. However, Newport et al. reported only 64% good to excellent results for simple extensor tendon injuries using postoperative static splinting, and they also reported difficulty with finger flexion.<sup>27</sup> Given the success of early mobilization after flexor tendon repairs, early dynamic mobilization and active mobilization protocols were introduced for extensor tendon repairs. Subsequently, many authors retrospectively demonstrated successful outcomes using these protocols.<sup>7,11,12,20</sup> More recently, several studies have prospectively investigated the differences between static immobilization, early dynamic mobilization, and early active mobilization protocols.

In 2005, Mowlavi et al. performed a randomized controlled trial comparing early dynamic mobilization with immobilization for zone V and VI lacerations.<sup>25</sup> They found significantly better total active motion (TAM) and grip strength in the early dynamic mobilization group at 8 weeks ( $p = .05$ ) but no difference at 6 months. The authors recommended early dynamic mobilization for highly motivated and compliant patients, but warned of increased risk of complications such as extensor tendon rupture and extensor lag. Bulstrode et al. also compared static immobilization with interphalangeal joint and MCP joint active mobilization after repair of zone V and VI lacerations.<sup>8</sup> Similar to Mowlavi, they found that both active mobilization groups demonstrated increased TAM at 4 weeks ( $p < .01$ ) but that no significant differences could be found at 3 months.<sup>8</sup>

In a randomized, controlled study in 2000, Khandwala compared dynamic active mobilization with active mobilization in zone V and VI extensor tendon repairs. Each group had 50 patients, but no statistical differences in TAM could be found.<sup>21</sup> In 2002, Chester performed a similar randomized, controlled trial comparing early active mobilization to early dynamic mobilization following surgical repair of zone IV to VIII extensor tendon injuries. Although early dynamic mobilization showed increased TAM at 4 weeks ( $p = .02$ ), no statistically significant differences could be found at 3 months.<sup>11</sup> The authors from both of these studies preferred the active mobilization protocol, given its ease of use.

Recently, Talsma et al. performed a systematic review to investigate the effectiveness of different mobi-

lization regimens on repaired extensor tendons in zones IV to VIII. They found 5 studies of sufficient quality to be included in their review. Overall, there was strong evidence for short-term superiority of early, controlled mobilization over immobilization in terms of range of motion and grip strength, but no conclusive evidence could be found regarding long-term benefits of any of the various protocols.<sup>34</sup>

Unlike flexor tendon injuries, extensor tendon injuries are frequently underestimated, and they have been given less attention in the literature. Despite recent advances of suture techniques and early mobilization of these injuries, definitive answers regarding optimal treatment algorithms still do not exist. Moving forward, there is a need for more level I evidence on this topic.

## REFERENCES

1. Ahmad F, Pickford M. Reconstruction of the extensor central slip using a distally based flexor digitorum superficialis slip. *J Hand Surg* 2009;34A:930–932.
2. Aiache A, Barsky AJ, Weiner DL. Prevention of the boutonniere deformity. *Plast Reconstr Surg* 1970;46:164–167.
3. Auchincloss JM. Mallet-finger injuries: a prospective, controlled trial of internal and external splintage. *Hand* 1982;14:168–173.
4. Baratz M, Schmidt C, Hughes T. Extensor tendon injuries. In: Green DP, Hotchkiss RN, Pederson WC, Wolfe SW, eds. *Green's operative hand surgery*. 5th ed. New York: Churchill Livingstone, 2005:187–217.
5. Bendre AA, Hartigan BJ, Kalainov DM. Mallet finger. *J Am Acad Orthop Surg* 2005;13:336–344.
6. Branovacki G, Hanson M, Cash R, Gonzalez M. The innervation pattern of the radial nerve at the elbow and in the forearm. *J Hand Surg* 1998;23B:167–169.
7. Brüner S, Wittmann M, Jester A, Blumenthal K, Germann G. Dynamic splinting after extensor tendon repair in zones V to VII. *J Hand Surg* 2003;28B:224–227.
8. Bulstrode NW, Burr N, Pratt AL, Grobbelaar AO. Extensor tendon rehabilitation: a prospective trial comparing three rehabilitation regimens. *J Hand Surg* 2005;30B:175–179.
9. Catalano LW III, Gupta S, Ragland R III, Glickel SZ, Johnson C, Barron OA. Closed treatment of nonrheumatoid extensor tendon dislocations at the metacarpophalangeal joint. *J Hand Surg* 2006;31A:242–245.
10. Celik S, Bilge O, Pinar Y, Govsa F. The anatomical variations of the extensor tendons to the dorsum of the hand. *Clin Anat* 2008;21:652–659.
11. Chester DL, Beale S, Beveridge L, Nancarrow JD, Titley OG. A prospective, controlled, randomized trial comparing early active extension with passive extension using a dynamic splint in the rehabilitation of repaired extensor tendons. *J Hand Surg* 2002;27B:283–288.
12. Chow JA, Dovel S, Thomes LJ, Ho PK, Saldana J. A comparison of results of extensor tendon repair followed by early controlled mobilisation versus static immobilisation. *J Hand Surg* 1989;14B:18–20.
13. Cluett J, Milne AD, Yang D, Morris SF. Repair of central slip avulsions using Mitek Micro Arc bone anchors. An *in vitro* biomechanical assessment. *J Hand Surg* 1999;24B:679–682.
14. Cricenti S, DeAngelis M, DiDio L, Ebraheim N, Rupp R, DiDio A. Innervation of the extensor carpi radialis brevis and supinator muscles: levels of origin and penetration of these muscular branches from the posterior interosseous nerve. *J Shoulder Elbow Surg* 1994;3:390–394.

15. Evans RB. Rehabilitation techniques for applying immediate active tension to the repaired extensor system. *Tech Hand Up Extrem Surg* 1999;3:139–150.
16. Gonzalez MH, Sohlberg R, Brown A, Weinzwieg N. The first dorsal extensor compartment: an anatomic study. *J Hand Surg* 1995;20A:657–660.
17. Handoll HH, Vaghela MV. Interventions for treating mallet finger injuries. *Cochrane Database Syst Rev* 2004;CD004574.
18. Husain SN, Dietz JF, Kalainov DM, Lautenschlager EP. A biomechanical study of distal interphalangeal joint subluxation after mallet fracture injury. *J Hand Surg* 2008;33A:26–30.
19. Kalainov DM, Hoepfner PE, Hartigan BJ, Carroll C IV, Genuario J. Nonsurgical treatment of closed mallet finger fractures. *J Hand Surg* 2005;30A:580–586.
20. Kerr CD, Burczak JR. Dynamic traction after extensor tendon repair in zones 6, 7, and 8: a retrospective study. *J Hand Surg* 1989;14B:21–22.
21. Khandwala AR, Webb J, Harris SB, Foster AJ, Elliot D. A comparison of dynamic extension splinting and controlled active mobilization of complete divisions of extensor tendons in zones 5 and 6. *J Hand Surg* 2000;25B:140–146.
22. Kinninmonth AW, Holburn F. A comparative controlled trial of a new perforated splint and a traditional splint in the treatment of mallet finger. *J Hand Surg* 1986;11B:261–262.
23. Lee SK, Dubey A, Kim BH, Zingman A, Landa J, Paksima N. A biomechanical study of extensor tendon repair methods: introduction to the running-interlocking horizontal mattress extensor tendon repair technique. *J Hand Surg* 2010;35A:19–23.
24. Maitra A, Dorani B. The conservative treatment of mallet finger with a simple splint: a case report. *Arch Emerg Med* 1993;10:244–248.
25. Mowlavi A, Burns M, Brown RE. Dynamic versus static splinting of simple zone V and zone VI extensor tendon repairs: a prospective, randomized, controlled study. *Plast Reconstr Surg* 2005;115:482–487.
26. Newport ML. Zone I–V extensor tendon repair. *Tech Hand Up Extrem Surg* 1998;2:50–55.
27. Newport ML, Blair WF, Steyers CM Jr. Long-term results of extensor tendon repair. *J Hand Surg* 1990;15A:961–966.
28. Newport ML, Pollack GR, Williams CD. Biomechanical characteristics of suture techniques in extensor zone IV. *J Hand Surg* 1995;20A:650–656.
29. Pratt AL, Burr N, Grobbelaar AO. A prospective review of open central slip laceration repair and rehabilitation. *J Hand Surg* 2002;27B:530–534.
30. Rayan GM, Murray D. Classification and treatment of closed sagittal band injuries. *J Hand Surg* 1994;19A:590–594.
31. Rubin J, Bozentka DJ, Bora FW. Diagnosis of closed central slip injuries. A cadaveric analysis of non-invasive tests. *J Hand Surg* 1996;21B:614–616.
32. Segalman KA. Dynamic lumbrical muscle transfer for correction of posttraumatic extensor tendon subluxation. *Tech Hand Up Extrem Surg* 2006;10:107–113.
33. Snow JW. A method for reconstruction of the central slip of the extensor tendon of a finger. *Plast Reconstr Surg* 1976;57:455–459.
34. Talsma E, de Haart M, Beelen A, Nollet F. The effect of mobilization on repaired extensor tendon injuries of the hand: a systematic review. *Arch Phys Med Rehabil* 2008;89:2366–2372.
35. Teoh LC, Lee JY. Mallet fractures: a novel approach to internal fixation using a hook plate. *J Hand Surg* 2007;32B:24–30.
36. Tetik C, Gudemez E. Modification of the extension block Kirschner wire technique for mallet fractures. *Clin Orthop Relat Res* 2002;404:284–290.
37. Warren RA, Norris SH, Ferguson DG. Mallet finger: a trial of two splints. *J Hand Surg* 1988;13B:151–153.
38. Woo SH, Tsai TM, Kleinert HE, Chew WY, Voor MJ. A biomechanical comparison of four extensor tendon repair techniques in zone IV. *Plast Reconstr Surg* 2005;115:1674–1681; discussion 1682–1683.
39. Zubović A, Egan C, O’Sullivan M. Augmented (Massachusetts General Hospital) Becker technique combined with static splinting in extensor tendons repairs zones III to VI: functional outcome at three months. *Tech Hand Up Extrem Surg* 2008;12:7–11.